

Case Report

Prenatal Diagnosis of Congenital Imperforate Hymen*

Bilgin GÜRATES, Ahmet KAZEZ, Ekrem SAPMAZ, Esra BULGAN, Murat YAYLA
 Departments of Obstetric and Gynecology and Pediatric Surgery, Firat University Faculty of Medicine-ELAZIĞ
 Department of Obstetrics and Gynecology, Dicle University Faculty of Medicine-DİYARBAKIR

SUMMARY**PRENATAL DIAGNOSIS OF IMPERFORATE HYMEN**

Background: The authors present two cases, which are prenatally diagnosed imperforate hymen, and are rarely observed in the prenatal period.

Observation: Two female fetuses with pelvic cystic masses which were possible hydrometrocolpos due to imperforate hymen (40x35 and 54x52 mm) were detected in the third trimester of pregnancy at 30th and 37th gestational weeks, during routine prenatal ultrasonography. Conservative management was preferred. Congenital imperforate hymen and hydrometrocolpos was confirmed after birth and each case was treated with hymenotomy.

Conclusion: Hydrocolpos and/or hydrometrocolpos resulting from congenital imperforate hymen should be remained in cases of fetal pelvic cystic mass in female fetuses and should be managed conservatively.

Key Words: Congenital imperforate hymen, Prenatal diagnosis.

ÖZET**İMPERFORE HİMENİN PRENATAL TANISI**

Amaç: Prenatal dönemde nadir olarak gözlenen iki imperfore himen olgusu erken tanı çerçevesinde sunuldu.

Olgular: İmperfore himene bağlı hidrometrokolposun oluşturduğu iki ayrı pelvik kistik kitle, gebeliğin 30 ve 37. haftalarında, iki ayrı dişi fetusta rutin ultrasonografi sırasında saptandı. Tedavi seçimi olarak konservatif yol tercih edildi. Doğumdan sonra ön tanımlar doğrulandı ve her iki yenidoğan himenotomi ile tedavi edildi.

Sonuç: Prenatal dönemde dişi fetuslarda pelvik kistik kitle ile karşılaşıldığında konjenital imperfore himene bağlı hidrokolpos ve/veya hidrometrokolpos da düşünülmeli ve mümkün olduğunca konservatif yaklaşılmalıdır.

Anahtar Kelimeler: Konjenital imperfore himen, Prenatal tanı

It is usually difficult to assess the female genital system with ultrasonography in the prenatal period. But if any liquid accumulates behind an existing cloacal malformation, the vagina and internal genital organs may become apparent (1). The congenital imperforate hymen is an external urogenital anomaly. It may present different findings under a careful antenatal ultrasonographic examination.

Besides presenting an image of mass in the mid-line of the fetal abdomen in the form of hydrocolpos and/or hydrometrocolpos it may also show a bloated membrane structure in the perineum between the separate labium (2). As hydrocolpos and/or hydrometrocolpos can be seen with

imperforate hymen, they can also be seen with transverse vaginal septum or vaginal agenesis (3).

Hydrocolpos can be palpated as a mass in the hypogastric region after birth or, as in many cases, it may present no findings until puberty. This condition can be easily identified in the neonatal period or puberty according to clinical findings and ultrasonography but its prenatal ultrasonographic diagnosis is rare. (1,4-7).

We have attempted to assess the diagnostic and clinical approach to the imperforate hymen, which is rarely observed in the prenatal period by presenting two cases of mass appearances in the fetal lower abdomen.

CASES

Case 1: During the control of a 25 year-old primigravida who had not received antenatal control previously, a pregnancy of 30 weeks in consis-

Yazışma Adresi: Ahmet Kazez

Department of Pediatric Surgery, Firat University, Firat Medical Center, Elazığ

*Presented at the 3rd Congress of the Obstetrics and Gynecology. May 19-23, 1999, Antalya

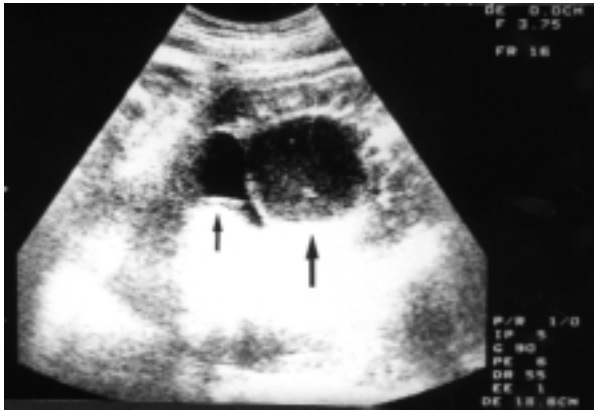


Figure 1: Prenatal ultrasonography shows a presacral, retrovesical cystic mass that is extending into the introitus (Small arrow: Bladder, Large arrow: Hydrocolpos).

tency with the last menstruation date was present. In the ultrasonography, an oval mass of 40x35mm with uniform echogenics was clearly observed in the fetal abdomen (Figure 1). The mass separated the boundaries with the sacrum in the posterior of the bladder and reached outward from the pelvis, also any dilatation of the gastrointestinal system was not observed. Except for the pressure caused by the mass, the structure and appearance of the bladder was found normal. The sex of the fetus was identified as female in the ultrasonography and the labium was found to be separated. No other anomalies were observed in the examination of the fetal anatomy. The amniotic fluid volume and placenta was normal. In the diagnosis of the mass, possibilities such as ovarian cyst, mesenteric cyst, anterior meningocele and its form developed in the anterior sacrococcygeal teratoma were considered. However, facts such as the fetus being identified as female and the separate condition of the labium make the diagnosis more likely that of congenital imperforate hymen and hydrometrocolpos. The conservative management was preferred

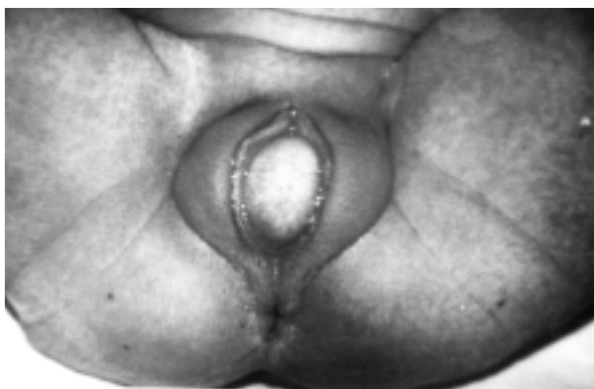

Figure 2: The preoperative photograph shows typical imperforate hymen.

and with regular antenatal checks it was observed that the mass did not grow further and during the 40th gestational week a baby girl weighing 3100 g was delivered by a spontaneous vaginal birth. During examination of the newborn, a mass was observed in the hypogastric region. The hymen swelled from the introitus when pressure was applied to the mass and it was observed to be imperforate (Figure 2). Upon an ultrasonographic examination of the newborn, an abdominopelvic mass structure consistent with the prenatal ultrasonography was observed. The uterus, cervix and vagina were dilated with hyperechogenic liquid. No anomaly was found in the other abdominal organs and hydrometrocolpos was provisionally diagnosed.

During the hymenotomy carried out at the Department of Pediatric Surgery, a white mucous liquid was emptied and therefore the hydrometrocolpos diagnosis was proved correct. Prophylactic antibiotics were prescribed. The ultrasonography carried out on the post operative 2nd day showed that the anatomy of the pelvic, abdominal and urinary systems were totally normal.

Case 2: During the first antenatal control of a 23-year-old primigravida at our clinic who had not received antenatal control previously, a pregnancy of 37 weeks in consistency with the last menstruation date was present. The structure and location of the mass in the abdomen was similar to the first case but the dimensions of this mass were 54x52 mm. The sex of the fetus was identified as female and the labium was obvious. During the 41st gestational week a baby girl weighing 3800 g was delivered by a spontaneous vaginal birth. In the examination, the abdomen was partially taut, and the hymen was obvious and imperforate between the labium. The diagnosis, observation and treatment procedures performed in the first case with the hydrometrocolpos provisionally diagnosis was also applied in this second case.

DISCUSSION

Until the late stages of fetal life the vaginal lumen is separate from the urogenital sinus by the hymen. The hymen is usually ruptured in the prenatal stage to provide a vaginal opening and remains at the vaginal entrance in the form of a mucous membrane (7). The inadequate rupture of this membrane causes an imperforate hymen. This obstruction at the exit of the vagina may cause hydrometra and/or hydrocolpos which are observed as pelvic masses arising from the accumulation of fetal cervical and vaginal secretions developed secondarily to the maternal hormonal stimulation (8).

The incidence of congenital imperforate hymen is very rare, ranging from 0.014 to 0.1 percent in babies which are born full-term (9). On average, neonatal hydrocolpos is found in 1 case in 16 000 newborn girls and in these series cloacal disgenesis, persistent urogenital sinus, vaginal stenosis are causes which are also included besides hydrocolpos and hydrometrocolpos (1,3).

Although the imperforate hymen is usually an isolated pathology, it can also be seen together with some anomalies such as ureter duplication and polydactyly, ectopic ureter, hypospadias, imperforate anus, and multicystic displastic kidneys (1,2,10). Also, a case evolving with only ascites was presented (11). An autosomal recessive transitional syndrome called the McKusick-Kaufman syndrome where hydrometrocolpos, polydactyly and cardiac malformations are found together has been identified (12). In a case with hydrocolpos diagnosed at the 30th gestational week the case included urethral obstruction, progressive hydronephrosis and oligohydramnios and dystocia developed at birth (1).

The above mentioned anomalies have not accompanied our cases and the masses have not developed enough to cause dystocia.

While making the differential diagnosis of hydrometrocolpos, possibilities such as ovarian cyst, mesenteric cyst, anterior meningocele and anterior sacrococcygeal teratoma should be considered in the prenatal period (13).

Early diagnosis and treatment is important in hydrometrocolpos. In some cases, hydrometrocolpos may cause urethral pressure causing bilateral hydronephrosis, oligohydramnios and developmental defects in the fetal lungs (1,3). Sometimes the mucus secretion may spread to the fetal peritoneum via retrograde and cause peritonitis (14). With the widespread use of ultrasonography it will be possible to diagnose and treat these cases much earlier. Shapiro has been reported that hydrometrocolpos due to uterovaginal anomalies can be seen as early as 26 weeks of gestation (15). When a cloacal anomaly is suspected in the diagnosis, the

heredity must be considered, and for those with additional anomalies following detailed ultrasonographies caryotyping must be performed. The most important issue in these cases is to ensure the healthy delivery of the fetus because postpartum drainage and, if necessary, any later reconstructive surgery will almost always be successful.

KAYNAKLAR

1. Geifman-Holtzman O, Crane SS, Winderl L, Holmes M. Persistent urogenital sinus: Prenatal diagnosis and pregnancy complications. *Am J Obstet Gynecol* 1997; 176: 709-11
2. Winderl LM, Silverman RK. Prenatal diagnosis of congenital imperforate hymen. *Obstet Gynecol* 1995; 85: 857-60
3. Westerhout FC, Hodgman JE, Anderson GV, Sack RA. Congenital hydrocolpos. *Am J Obstet Gynecol* 1964; 89: 957-61
4. Abraham D, Koenigsberg M, Hoffman-Tretin J. The prenatal ultrasound appearance of hydrometrocolpos. *J Diagn Med Sonography* 1985; 1: 115-6
5. Hill SJ, Hirsch JH. Sonographic detection of foetal hydrometrocolpos. *J Ultrasound Med* 1985; 4: 323-5
6. Nussbaum-Blask AR, Sanders RC, Gearhart JP. Obstructed uterovaginal anomalies: demonstration with sonography-part I: neonates and infants. *Radiology* 1991; 179: 79-83
7. Moore KL. The urogenital system. In: Moore KL, Persaud TVN (eds). *The Developing Human: Clinically Oriented Embryology*. (6th ed) Philadelphia, WB Saunders, 1998: 255-97
8. Chen CP, Liu FF, Jan SW, Chang PY, Lin YN, Lan CC. Ultrasound-guided fluid aspiration and prenatal diagnosis of duplicated hydrometrocolpos with uterus didelphys and septate vagina. *Prenatal Diag* 1996; 16: 572-6
9. Wilkinson EJ, Friedrich EG. Diseases of the vulva. In: Kurmann RI (ed). *Blaustein's Pathology of the Female Genital Tract* (3rd ed). New York, Springer-Verlag, 1987; 36-96
10. Iuchtman M, Assa J, Blatnoi I. Hydrometrocolpos associated with retroiliac ureter. *J Urol* 1980; 124: 283-5
11. Jacquemyn Y, De Catte L, Vaerenberg M. Foetal ascites associated with an imperforate hymen: sonographic observation. *Ultrasound Obstet Gynecol* 1998; 12: 67-9
12. Robinow M., Shaw A. The McKusick-Kaufman syndrome: recessively inherited vaginal atresia, hydrometrocolpos, uterovaginal duplication, anorectal anomalies, postaxial polydactyly, and congenital heart disease. *J Pediatr* 1979; 94: 776-8
13. Romero R. *Prenatal Diagnosis of Congenital Anomalies*. Norwalk, Appleton & Lange, 1985: 305-7
14. Ceballos R, Hicks GM. Plastic peritonitis due to neonatal hydrometrocolpos: Radiologic and pathologic observations. *J Pediatr Surg* 1970; 5: 63-70
15. Shapiro E. The sonographic appearance of normal and abnormal fetal genitalia. *J Urol* 1999; 162: 530-3