

Case Report

Thanatophoric Dysplasia: Report of Three Cases

Recai Soner ÖNER, Dilek ASLAN, Ahmet GÜLER, Sevil SEYHAN
SSK Aegean Maternity and Teaching Hospital, Department of Perinatology - İZMİR

SUMMARY**THANATOPHORIC DYSPLASIA: REPORT OF THREE CASES**

Background: Thanatophoric dysplasia is a rare osteochondrodysplasia, with an incidence about 1:20000 pregnancies. It is a lethal disorder characterized by short ribs, tubular bones and macrocephaly. Death is often secondary to pulmonary hypoplasia.

Observations: We present a series of three cases in which the diagnosis was reached at routine prenatal scanning. All three patients underwent termination of pregnancy and postmortem radiological and hystological examinations confirmed the diagnosis. Characteristic features of thanatophoric dysplasia are discussed by means of the ultrasonographic and radiographic images of cases.

Conclusion: Thanatophoric dysplasia is characterized by caustic skeletal deformities can easily be detected by prenatal ultrasonography. This paper emphasizes the importance of prenatal ultrasonography in describing fetal malformations.

Key words: Thanatophoric dysplasia, Prenatal ultrasonography

ÖZET**TANATOFORİK DİSPLAZİ: 3 OLGUNUN SUNUMU**

Amaç: Tanatoforik displazi, nadir görülen fatal seyirli bir osteokondroplazidir. Karakteristik özellikleri ekstremitelerde uzun kemiklerinde kısalık, makrosefali, kosta kısalığına bağlı göğüs kafesi darlığı ve polihidramniosdur. Pulmoner hipoplazi şiddetlidir ve mortalite sebebidir. Neonatal letal kısa ekstremiteli cücelik tipleri içinde en sık tanatoforik displazi görülür.

Olgular: Bu yayında, prenatal ultrasonografi ile tanatoforik displazi tanısı konulan 3 olguyu sunuyoruz. Olgular, gebelik terminasyonu sonrası radyolojik ve patolojik olarak da bu tanıyı aldılar. Her 3 olgu da postmortem sitogenetik incelemeye tabi tutuldu. Olguların özellikleri, ultrasonografik ve radyolojik görüntüleri sunulmaktadır.

Sonuç: İskelet deformitesi ile seyreden tanatoforik displazi prenatal ultrasonografi ile kolay tanınabilir.

Anahtar Kelimeler: Tanatoforik displazi, Prenatal ultrasonografi

Thanatophoric dysplasia (TD) is a rare, lethal osteochondrodysplasia (1). This term was first described and used by Maroteux for dwarf babies who died in first hour of life (2). Characteristic features of TD are; short tubular bones, short ribs, narrow (pear-shaped) chest with protuberant abdomen, macrocephaly and polyhydramnios (2, 3). Death is often secondary to pulmonary hypoplasia caused by small thoracic cavity (3). TD is the most frequent type in lethal neonatal short-limbed dysplasia groups (4). Langer et al. proposed that TD could be divided into two groups (TD-1 and TD-2) based on the presence of straight or curved femora (5). TD-1 is characterized by curved femo-

ra, which is typically called 'Telephone Receiver Shape'. Whereas, TD-2 type with straight femora is almost associated with 'Cloverleaf Skull'.

We report three cases of TD-1 in which the diagnosis is reached prenatally with prenatal routine scanning.

CASES

Case-1; 33 year-old, G1P0, admitted at 22nd gestational week. Case-2; 28 year-old, G1P0, admitted at 23rd gestational week. Case-3; 34 year-old, G4P3, admitted at 32nd gestational week. Obstetric, medical and family histories of all cases were negative for any adverse outcome.

Main abnormalities in all three cases were: tetramicromelia (shortened bowed limbs), 'telephone

Table 1. Ultrasonographic Measurements of the Cases

	MEASUREMENTS (WEEK & PERCENTILE)*					
	CASE-1		CASE-2		CASE-3	
BPD	22+5	50 th	23+3	50 th	41	>95th
FL	15+3	<5 th	14+4	<5 th	17	<5 th
FAC	22+3	50 th	23+1	50 th	32	50 th
ULNA	14+4	<5 th	14+1	<5 th	19+6	<5 th
TIBIA	14+6	<5 th	15+4	<5 th	18	<5 th
HUMERUS	14+4	<5 th	14+6	<5 th	19+6	<5 th

*The first column shows gestational week and the second shows percentile of the measurement for each case.

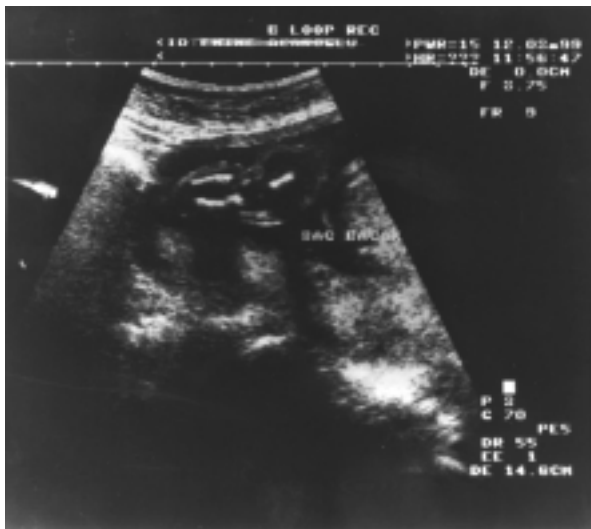

Figure- 1: Ultrasonographic appearance of shortened bowed extremity bones.

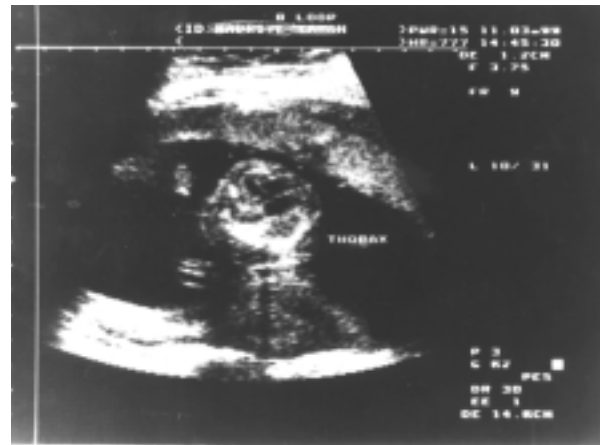

Figure 3: Axial section of thorax. Increased cardiothoracic ratio secondary to narrowed thoracic cavity.

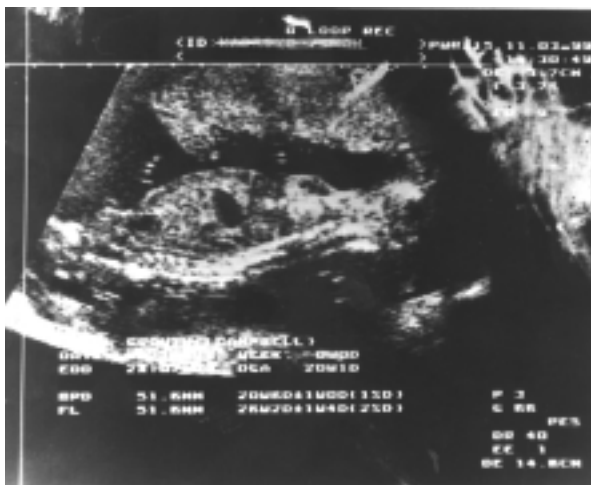

Figure 2. Ultrasonography shows narrow chest with protuberant abdomen.

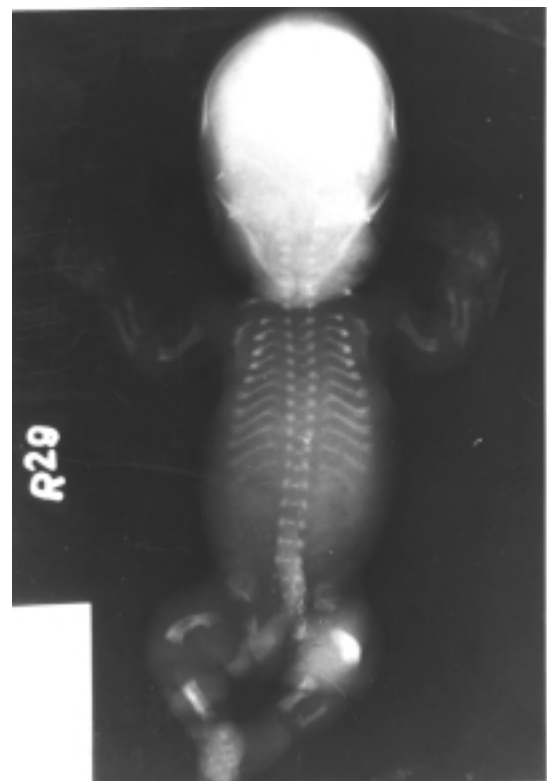


Figure 4: Radiographic demonstration of typical features. Short ribs (pear-shaped chest), telephone receiver- shaped femora, and macrocephaly.

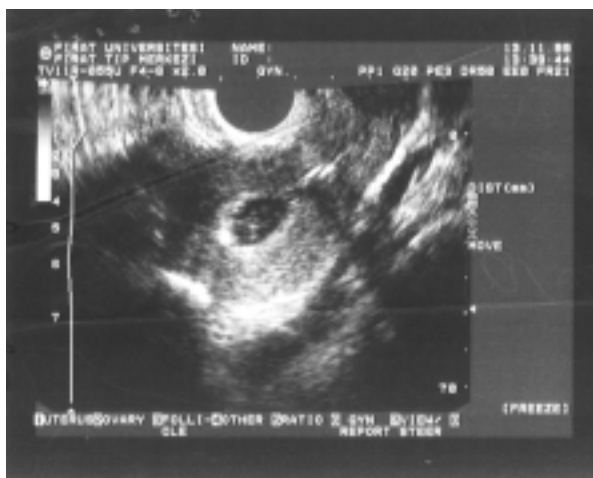

Figure- 5: Newborn with TD. Tetramicromelia, narrow chest with protuberant abdomen.

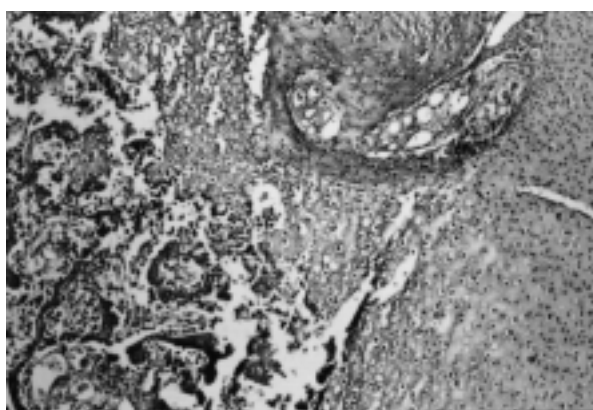


Figure- 6: Histopathological appearance of the bone and cartilage: severely retarded and disorganized physal growth zone (HE x 200).

receiver shaped' femora, 'pear-shaped' chest, protuberant abdomen and polyhydramnios (Table-1, Figure-1, Figure-2, Figure-3). Case-3 additionally showed severe hydrocephaly and absent cavum septum pellucidum. All three cases were diagnosed as TD and terminations of pregnancies were performed by using Misoprostol in first and second cases. Because of the cephalo-pelvic-disassociation caused by severe hydrocephaly, third case underwent cesarean section. The diagnoses were confirmed with postmortem radiographic and macroscopic features in all three cases. (Figure- 4, Figure- 5).

Cytogenetic evaluation revealed 47, XXY in Case-1, 46, XY, 1qh+ in Case-2 and 46, XY, inv (11) in Case-3.

Histopathology of the bone and cartilage showed a severely retarded and disorganized physal growth zone (Figure- 6).

DISCUSSION

TD is a lethal osteochondrodysplasia and is the most common type of neonatal short-limbed dysplasias (1, 4). Abnormal growth and development of bone and cartilage characterize this rare disorder (6). Abnormal ossification results from mutations on the Fibroblast Growth Factor Receptor-3= FGRF-3. The severity and the type of this mutation affect clinical and pathological features (7). In different population based studies, the recurrence risk of TD is reported about 2% and its genetic base is not well documented (8). Although there are familial cases in literature, proposed genetic recessivity is not proven and finally most authors concluded its autosomal dominant or polygenic inheritance and genetic heterogeneity (9).

The abnormalities in our all three cases were; tetramicromelia (shortened bowed limbs), 'telephone receiver shaped' femora, 'pear-shaped' chest, protuberant abdomen, macrocephaly and polyhydramnios similar to those reported in literature. All three patients were diagnosed as TD- 1. Cytogenetic abnormalities seen in Case-1 and 3 were very interesting and thought to be remarks of the proposed genetic heterogeneity of TD. In case 1, Klinefelter syndrome is detected. Association of TD and Klinefelter syndrome has not been reported before this case. And also, inv (11) abnormality has not been depicted before. 1qh+ heterochromatin polymorphism is accredited as a normal variant.

Although TD is generally fatal in the first hours of life, unusual cases those living up to 9-year-old are also reported in literature (10). Death is often secondary to severe pulmonary hypoplasia caused by small thoracic cavity (3).

It is reported that fatal skeletal dysplasias can be detected 97% with ultrasonography, but specific diagnosis is possible at only half of them (11). Ultrasonography is not enough for differentiation of TD, Achondroplasia, Osteogenesis Imperfecta, Campomelic Syndrome and Short Rib Syndromes from each other. Radiography and, clinical and histopathological examination are also essential for precise diagnosis (12).

REFERENCES

1. Orioli I, Castilla EE, Barbosa-Neto JG. The birth prevalence rates for the skeletal dysplasias. *J Med Genet*, 1986; 23: 328-32
2. Maroteux P, Lamy M, Robert JM. Thanatophoric dysplasia: an autosomal dominant condition? *Am J Med Genet*, 1988; 31: 815-20
3. Gerihauser H, Schuster C, Immervoll H, Sochor G. Prenatal diagnosis of thanatophoric dwarfism. *Ultraschall Med*, 1992; 13: 41-5
4. Van der Harten HJ, Brons JT, Dijkstra PF, Barth PG, Niermeyer MF. Same variants of lethal neonatal short-limbed platyspondylic dysplasia: a radiological, ultrasonographic, ne-

- urapathological and hystopathological study of 22 cases. *Clin Dysmorphol*, 1993; 2: 1-19
5. Langer LO Jr, Yang SS, Hall JG, Sommer A, Kottamasu SR, Golabi M. Thanatophoric dysplasia and cloverleaf skull. *Am J Med Genet Suppl*, 1987; 3: 167-79
 6. Horton WA, Hood OJ, Machado MA, Ahmed S, Griffey ES. Abnormal ossification in thanatophoric dysplasia. *Bone*, 1988; 9: 53-61
 7. Tavormina PL, Shiang R, Thompson LM, Zhu YZ, Wilkin DJ, Lachman RS. Thanatophoric dysplasia (types I and II) caused by distinct mutations in fibroblast growth factor receptor 3. *Nat Genet* 1995; 9: 321-8
 8. Pena SDJ, Goodman HO. The genetics of thanatophoric dwarfism. *Pediatrics*, 1973; 51: 104-9
 9. Reardon W, Winter RM, Rutland P, Pulleyn LJ, Jones BM, Malcolm S. Mutations in the fibroblast growth factor receptor 2 gene cause Crouzon Syndrome. *Nature Genet*, 1994; 8: 98-103
 10. Baker KM, Olson DS, Harding CO, Panli RM. Long-term survival in typical thanatophoric dysplasia type 1. *Am J Med Genet*, 1997; 70: 427-36
 11. Tretter AE, Saunder RC, Meyers CM, Dungan JS, Grumbach K. Antenatal diagnosis of lethal skeletal dysplasias. *Am J Med Genet*, 1998; 17: 75: 518-22
 12. Pretorius DH, Rumack CM, Manco-Johnson ML, Manchester D, Meier P. Specific skeletal dysplasias in utero: sonographic diagnosis. *Radiology*, 1986; 159: 237-42